American Journal of

# Biochemistry and Molecular Biology

ISSN 2150-4210

Academic
Journals Inc.

www.academicjournals.com

OPEN ACCESS American Journal of Biochemistry and Molecular Biology

ISSN 2150-4210
DOI: 10.3923/ajbmb.2016.1.14

Research Article

# Alpha-lipoic Acid Protects Rat Kidney Against Oxidative Stress-Mediated DNA Damage and Apoptosis Induced by Lead

[1]Samy Ali Hussein, [1]Mohamed Ragaa R. Hassanein, [2]Aziza Amin and [1]Asmaa H. Mohammad Hussein

[1]Department of Biochemistry, Faculty of Veterinary Medicine, Benha University, Moshtohor, Egypt
[2]Department of Pathology, Faculty of Veterinary Medicine, Benha University, Moshtohor, Egypt

## Abstract

**Objective:** The protective effects of alpha-lipoic acid against lead (Pb) induced oxidative stress to kidney tissues in rats were evaluated. **Materials and Methods:** Eighty male albino rats were divided into 4 equal groups. Group 1: (control) administered distilled water. Group 2 received lead acetate orally (30 mg $kg^{-1}$ b.wt., of 1/20th of $LD_{50}$). Group 3 received lead (30 mg $kg^{-1}$ b.wt.) plus alpha-lipoic acid (54 mg $kg^{-1}$ b.wt./day/i.p). Group 4: received alpha-lipoic acid (54 mg $kg^{-1}$ b.wt.). Blood samples were collected for determination of serum TNF-α, IL-6, IL-1β. Also, kidney tissues were taken and processed for L-MDA, CAT, SOD,GPx, DNA fragmentation, caspase-3, NF-kB P65, 8-OhdG and Cox-2. Additionally, liver and kidney specimens were excised for histopathological examination and lead residues determination. **Results:** The obtained results showed significant increase in serum TNF-α, IL-6 and IL-1β, kidney tissues L-MDA, DNA fragmentation, caspase-3, NF-kB P65, 8-OhdG and Cox-2 in addition to liver and kidney lead residue in lead intoxicated rats. However, administration of alpha-lipoic acid exhibited a significant decreased in all mentioned parameters. Kidney tissues antioxidant enzymes were markedly decreased in lead intoxicated rats and the activities were attenuated after treatment with alpha-lipoic acid. Various pathological alterations were observed in liver and kidney of lead administered group. Interestingly, the histopathological results supported that alpha-lipoic acid markedly reduced the deleterious effect induced by Pb and preserved the normal histological architecture of the liver and kidney tissues. **Conclusion:** The results indicate that, alpha-lipoic acid could be applicable as a cytoprotective against oxidative stress of tissue damage mediated by heavy metals intoxication as confirmed by biochemical and histopathological results.

Key words: Lead toxicity, alpha-lipoic acid, DNA damage, pro-inflammatory cytokines, histopathological changes, oxidative stress, apoptosis

Received: November 18, 2015 Accepted: December 03, 2015 Published: December 15, 2015

Citation: Samy Ali Hussein, Mohamed Ragaa R. Hassanein, Aziza Amin and Asmaa H. Mohammad Hussein, 2016. Alpha-lipoic acid protects rat kidney against oxidative stress-mediated DNA damage and apoptosis induced by lead. Am. J. Biochem. Mol. Biol., 6: 1-14.

Corresponding Author: Samy Ali Hussein Aziza, Faculty of Veterinary Medicine, Benha University, Moshtohor, Toukh, P.O. Box 13736, Kaliobia, Egypt
Tel: 00201060754457 Fax: 0020132460640

Copyright: © 2016 Samy Ali Hussein *et al.* This is an open access article distributed under the terms of the creative commons attribution License, which permits unrestricted use, distribution and reproduction in any medium, provided the original author and source are credited.

Competing Interest: The authors have declared that no competing interest exists.

Data Availability: All relevant data are within the paper and its supporting information files.

## INTRODUCTION

Lead (Pb), one of the oldest known metals, is a pervasive and persistent environmental occupational toxic metal and Pb poisoning remains a health threat[1]. It is a dangerous heavy metal and harmful even in small amounts. Nevertheless, humans get exposed to Pb through their environment and diet so that, more than 75% of lead-exposure for the general population comes from ingestion[2]. Lead absorption by ingestion depends on factors such as the particle size, physical form, gastrointestinal transit time and nutritional status of a person. Lead absorption increases, with increasing age, making children and infants more vulnerable to lead intoxication[3]. The manifestations of Pb poisoning in humans are nonspecific. They may include weight loss, anemia, memory loss, nephropathy, infertility as well as liver, testis and heart damages[4].

Lead-induced oxidative stress in blood, corpus cell and other soft tissues has been postulated to be one of the possible mechanisms of lead-induced toxic effects[5]. Disruption of pro-oxidant/antioxidant balance might led to the tissue injury. It was reported that lead increased the level of lipid peroxidation[6]. Also, induced kidney injury was related to the increase production of Reactive Oxygen Species (ROS) and to induce oxidative stress, excitotoxicity, DNA damage and apoptosis[7]. However, the histopathological changes in different tissues due to lead toxicity are dose dependent[8]. Although, kidneys and liver play a principle role in the removal of lead from the body[9], there was little available literature about the detailed renal and hepatic pathological changes in lead toxicity.

Antioxidants are substances, inhibit or delay oxidation of a substrate while present in minute amounts. They easily oxidized by ROS in a biological system, decreasing the rate at which the ROS react with cellular components like lipid membranes, DNA, or proteins. The most important source of antioxidants is provided by nutrition[10].

Alpha-lipoic acid is water and lipid soluble, a property that allows it to concentrate in cellular and extracellular environments. Exogenous Lipoic Acid (LA) is rapidly absorbed from the diet and is reduced inside the cell to dihydrolipoic acid (DHLA), the most active form of the substance[11]. Alpha-lipoic acid (LA) is a naturally occurring compound which functions as a cofactor in several mitochondrial multienzyme complexes involved in energy production in humans and animals[12]. The LA acts as coenzyme of pyruvate and the alpha-ketoglutarate dehydrogenase multienzyme complex of the tricarboxylic acid cycle and has metal chelating, free radical scavenging and antioxidant-regenerating abilities[13]. It protects against oxidative stress both in peripheral tissues and central nervous system[14].

However, acute and chronic exposure to lead resulting in alteration in lipid peroxidation which harm cell membrane and DNA causing hematological, immunological, reproductive, neurological and gastrointestinal pathological changes. On the other hand, the addition of antioxidants could decline these changes[15]. Accordingly, the present study was designed to investigate the beneficial effects of alpha-lipoic acid on biomarkers of oxidative stress and antioxidant enzymatic status in kidney tissues in addition to changes of serum pro-inflammatory cytokines in lead intoxicated rats. Additionally, the protective effect of alpha-lipoic acid against nephrotoxicity and hepatotoxicity of lead intoxicated rats were also evaluated.

## MATERIALS AND METHODS

The current study was done concluded in the period between January and October, 2014. Eighty male albino rats of 8-10 weeks old and weighing 200-250 g were used in this study. Rats were housed in separated metal cages and kept at constant environmental and nutritional conditions throughout the period of experiment. The animals were fed on constant ration and water was supplied *ad libitum*. All rats were acclimatized for minimum period of two weeks prior to the beginning of study.

**Chemicals and drugs:** All chemicals were of analytical grade and obtained from standard commercial suppliers. The drug and chemicals used in the present study were:

- **Lead acetate:** Lead acetate has molecular weight 379.33. Each one gram of lead acetate 72% contains 521 mg of lead. It was provided by Riedel-de Haen Ag Seelze-Hannover, west company. Lead acetate was dissolved in distilled water, freshly prepared and administered orally and daily at a dose level of 30 mg $kg^{-1}$ b.wt. (1/20 of $LD_{50}$)
- **Alpha-lipoic acid (thiotacid)®:** Thiotacid was obtained as pack of five ampoules of 10 mL solution. Each ampoule contains thioctic acid (alpha lipoic acid) 300 mg. Alpha-lipoic acid (thioctic acid)® manufactured by EVA pharma for pharmaceuticals and medical apliances, Egypt. Alpha lipoic acid was injected intraperetineal in a daily dose of 54 mg $kg^{-1}$ b.wt.[16]

**Experimental design:** After acclimatization to the laboratory conditions, the animals were randomly divided into 4 groups (20 rats each) placed in individual cages and classified as follow:

- **Group 1 (control normal group):** Rats received no drugs, served as control non-treated for all experimental groups
- **Group 2 (lead acetate exposed group):** Rats received lead acetate 1/20 of $LD_{50}$ (30 mg $kg^{-1}$ b.wt.) orally and once per day over a period of 10 weeks
- **Group 3 (lead acetate+Alpha-lipoic acid treated group):** Rats received lead acetate (30 mg $kg^{-1}$ b.wt.) and treated daily with alpha-lipoic acid (54 mg $kg^{-1}$ b.wt./i.p)
- **Group 4 (alpha-lipoic acid treated group):** Rats administered daily with alpha-lipoic acid (54 mg $kg^{-1}$ b.wt./i.p)

### Sampling

**Blood samples:** Blood samples were collected in dry, clean test tubes and allowed to clot for 30 min and serum was separated by centrifugation at 3000 rpm for 15 min. The serum was separated by automatic pipette and received in dry sterile tubes, then kept on deep freeze at -20°C until use for subsequent biochemical analysis. All sera were analyzed for the following parameters: TNF-α, IL-6 and IL-1β.

**Kidney tissue specimens for biochemical analysis:** Rats killed by decapitation. The kidney specimens were quickly removed, cleaned by rinsing with cold saline and stored at -20°C. Briefly, renal tissues was minced into small pieces, homogenized with ice cold 0.05 M potassium phosphate buffer (pH 7.4) to make 10% homogenates. The homogenates were be centrifuged at 6000 rpm for 15 min at 4°C, then the resultant supernatant were directly used for determination of the following parameters: L-MDA, CAT, SOD, GPx, DNA fragmentation, Caspase-3, NF-kB P65, 8-OhdG and Cox-2.

### Tissue specimen (liver and kidney)

**For determination of lead residue:** Liver and kidney specimen were taken from each group of rats after had been sacrificed at 8 and 10 weeks of the experiment. The specimens were quickly removed and washed several times with saline, weighed and processed for determination of lead residues by using atomic absorption spectrophotometer as described by Al-Ghais[17].

**For histopathological examination:** Liver and kidney specimen of rats were carefully examined by naked eyes for detection of any abnormalities. Small specimen was taken from these organs. These samples were fixed in 10% buffered neutral formalin solution. Then after proper fixation, the samples were dehydrated in ascending grades of ethyl alcohol, then cleared in xylol, embedded in paraffin and finely blocking occurred. These samples were sectioned at 5 µm in thickness and stained with hematoxylin and eosin (H and E) for microscopical examination[18].

**Biochemical analysis:** Serum TNF-α, IL-6 and IL-1β were determined according to the method described by Beyaert and Fiers[19], Chan and Perlstein[20] and Rat IL-1 beta ELISA (RayBiotech, Inc Company, Cat#: ELR-IL1b), respectively. Moreover, L-MDA, CAT, SOD, GPx, DNA fragmentation, caspase-3, NF-kB P65, 8-OhdG and Cox-2 were determined according to the method described by Esterbauer *et al.*[21], Sinha [22], Packer and Glazer[23], Gross *et al.*[24], Necheles *et al.*[25] and Shi *et al.*[26], (Casp-3) ELISA Kit (CUSABIO BIOTECH CO., LTD.), Cat.No.CSB-E08857r), ELISA Kit (Cat.No. MBS814487), EIA Kits (Cat# SKT-120-96 (96 well kit), Cat# SKT-120-480 (480 well kit) and COX-2 ELISA Kit (Cat.No. E0699m), respectively.

**Statistical analysis:** The results were expressed as mean±SE and statistical significance was evaluated by one way ANOVA using SPSS (version 10.0) program followed by the *post hoc* test, Least Significant Difference (LSD). The Values were considered statistically significant when $p<0.05$.

## RESULTS

**Serum TNF-α, IL-6 and IL-1β concentrations:** The obtained results demonstrated in (Table 1 and 2) revealed that, lead intoxicated rats showed significant increase in serum TNF-α, IL-6 and IL-1β concentrations when compared with normal control group. Treatment with alpha-lipoic acid to lead intoxicated rats caused significant decrease serum TNF-α, IL-6 and IL-1β concentrations when compared with lead intoxicated group.

**Kidney tissues L-MDA concentration, CAT, SOD and GPx activities:** The results illustrated in (Table 1 and 2) revealed that, lead intoxicated rats showed significant increase in kidney tissues L-MDA concentration with significant decrease in kidney tissues CAT, SOD and GPx activities allover the periods of the experiment when compared with normal control group. Treatment with alpha-lipoic acid to lead intoxicated male rats caused significant decrease in kidney tissues L-MDA concentrations and significant increase in kidney tissues CAT, SOD and GPx activities when compared with lead exposed group.

Table 1: Protective effects of alpha- lipoic acid on some serum pro-inflammatory cytokines and kidney tissue biochemical markers in lead intoxicated rats and their control

| | Eight weeks treatment | | | |
|---|---|---|---|---|
| Experimental groups | Control | Lead | Lead+lipoic acid | Lipoic acid |
| **Parameters** | | | | |
| TNF-α (pg $mL^{-1}$) | 19.300±4.37$^{c}$ | 93.00±7.24$^{a}$ | 48.680±3.13$^{b}$ | 19.030±2.80$^{c}$ |
| IL-6 (pg $mL^{-1}$) | 48.050±8.42$^{b}$ | 157.90±10.68$^{a}$ | 63.670±7.46$^{b}$ | 48.600±14.42$^{b}$ |
| IL-1β (pg $mL^{-1}$) | 210.640±53.49$^{c}$ | 761.12±85.38$^{a}$ | 465.500±35.03$^{b}$ | 147.820±15.05$^{c}$ |
| MDA (mmol $g^{-1}$ tissue) | 80.250±3.19$^{b}$ | 160.50±15.09$^{a}$ | 67.460±8.61$^{b}$ | 28.780±2.28$^{c}$ |
| CAT (mmol $g^{-1}$ tissue) | 49.750±2.67$^{a}$ | 19.86±3.16$^{b}$ | 48.340±2.54$^{a}$ | 57.140±1.82$^{a}$ |
| SOD (U $g^{-1}$ tissue) | 33.490±4.73$^{a}$ | 7.43±2.44$^{c}$ | 19.730±3.47$^{b}$ | 39.110±2.71$^{a}$ |
| GPx (ng $g^{-1}$ tissue) | 28.540±2.20$^{a}$ | 13.80±0.987$^{c}$ | 21.070±0.735$^{b}$ | 34.890±3.21$^{a}$ |
| DNA fragmentation (cells/well tissue) | 120.580±28.94$^{b}$ | 1297.34±234.81$^{a}$ | 448.140±69.39$^{b}$ | 71.830±3.25$^{b}$ |
| 8-OhdG (pg $g^{-1}$ tissue) | 105.030±13.29$^{b}$ | 259.92±23.62$^{a}$ | 144.480±15.96$^{b}$ | 124.280±21.39$^{b}$ |
| NF-κB p65 (ng $g^{-1}$ tissue) | 4.200±0.500$^{c}$ | 11.72±0.633$^{a}$ | 6.760±0.113$^{b}$ | 3.670±1.04$^{c}$ |
| COX-2 (U $g^{-1}$ tissue) | 4.130±0.306$^{b}$ | 11.10±1.41$^{a}$ | 6.330±0.445$^{b}$ | 4.040±1.14$^{b}$ |
| Caspase-3 (ng $g^{-1}$ tissue) | 0.335±0.044$^{c}$ | 1.38±0.103$^{a}$ | 0.719±0.043$^{b}$ | 0.396±0.053$^{c}$ |

Data are presented as (Mean±SE), SE: Standard error, mean values with different superscript letters in the same row are significantly different at ($p<0.05$)

Table 2: Protective effects of alpha-lipoic acid on some serum pro-inflammatory cytokines and kidney tissue biochemical markers in lead intoxicated rats and their control

| | Ten weeks treatment | | | |
|---|---|---|---|---|
| Experimental groups | Control | Lead | Lead+lipoic acid | Lipoic acid |
| **Parameters** | | | | |
| TNF-α (pg $mL^{-1}$) | 34.070±6.91$^{b}$ | 74.04±5.01$^{a}$ | 40.620±4.27$^{b}$ | 23.680±5.44$^{b}$ |
| IL-6 (pg $mL^{-1}$) | 56.760±9.91$^{b}$ | 158.42±15.15$^{a}$ | 67.850±21.85$^{b}$ | 45.730±9.91$^{b}$ |
| IL-1β (pg $mL^{-1}$) | 254.160±55.45$^{b}$ | 831.98±48.49$^{a}$ | 333.820±65.25$^{b}$ | 194.040±71.24$^{b}$ |
| MDA (mmol $g^{-1}$ tissue) | 69.180±7.10$^{b}$ | 171.59±9.49$^{a}$ | 71.430±10.52$^{b}$ | 53.440±7.60$^{b}$ |
| CAT (mmol $g^{-1}$ tissue) | 45.930±4.96$^{a}$ | 21.98±5.95$^{b}$ | 46.570±3.85$^{a}$ | 57.320±3.74$^{a}$ |
| SOD (U $g^{-1}$ tissue) | 28.370±2.96$^{b}$ | 6.21±2.13$^{d}$ | 15.780±0.586$^{c}$ | 42.790±2.30$^{a}$ |
| GPx (ng $g^{-1}$ tissue) | 23.170±1.13$^{b}$ | 10.67±1.80$^{c}$ | 17.620±1.88$^{b}$ | 30.410±2.17$^{a}$ |
| DNA-fragmentation 0 (cells/well tissue) | 146.340±70.07$^{b}$ | 1333.06±193.21$^{a}$ | 397.270±51.33$^{b}$ | 73.400±29.53$^{b}$ |
| 8-OhdG (pg $g^{-1}$ tissue) | 131.780±32.56$^{b}$ | 242.32±14.16$^{a}$ | 149.980±9.64$^{b}$ | 119.640±27.56$^{b}$ |
| NF-κB p65 (ng $g^{-1}$ tissue) | 3.940±1.53$^{b}$ | 12.52±1.36$^{a}$ | 5.510±0.971$^{b}$ | 3.930±1.49$^{b}$ |
| COX-2 (U $g^{-1}$ tissue) | 4.730±0.858$^{cb}$ | 10.20±1.034$^{a}$ | 7.040±0.519$^{b}$ | 3.640±0.595$^{c}$ |
| Caspase-3 (ng $g^{-1}$ tissue) | 0.317±0.081$^{c}$ | 1.43±0.172$^{a}$ | 0.678±0.044c$^{b}$ | 0.377±0.075c$^{b}$ |

Data are presented as (Mean±SE), SE: Standard error, mean values with different superscript letters in the same row are significantly different at ($p<0.05$)

**Kidney tissues DNA fragmentation and caspase-3 activity:** Kidney tissues DNA fragmentation and caspase-3 activity increased significantly in lead exposed rats all over the periods of the experiment when compared with normal control group. Treatment with alpha-lipoic acid to lead intoxicated male rats caused significant decrease in kidney tissues DNA fragmentation and caspase-3 activity when compared with lead exposed group (Table 1 and 2).

**Kidney tissues NF-kB P65, 8-OhdG concentrations and Cox-2 activity:** The obtained data revealed that, kidney tissues NF-kB P65,8-OhdG concentrations and Cox-2 activity increase significantly in lead exposed rats. Treatment with alpha-lipoic acid to lead intoxicated rats caused a significant decrease in kidney tissues NF-kB P65, 8-OhdG concentrations and Cox-2 activity when compared with lead exposed group (Table 1 and 2).

**Kidney and liver lead residues concentration:** The obtained results presented in (Table 3) revealed that the mean value of kidney and liver lead residues concentrations increased significantly in lead exposed rats when compared with normal control group. Treatment with alpha-lipoic acid to lead intoxicated male rats resulted in significant decrease in kidney and liver lead residues concentrations when compared with lead exposed group.

**Histopathological findings:** The examined kidneys of rats administered lead acetate (30 mg $kg^{-1}$ b.wt./day) in drinking water for 10 weeks revealed congestion of the renal blood vessels and intertubular capillaries. The renal cortex showed enlarged glomeruli with hypercellularity of glomerular tufts characterized by proliferation of the lining epithelial cells of glomerular capillaries and the Bowman's capsule was completely filled with glomerular tuft with absence of the

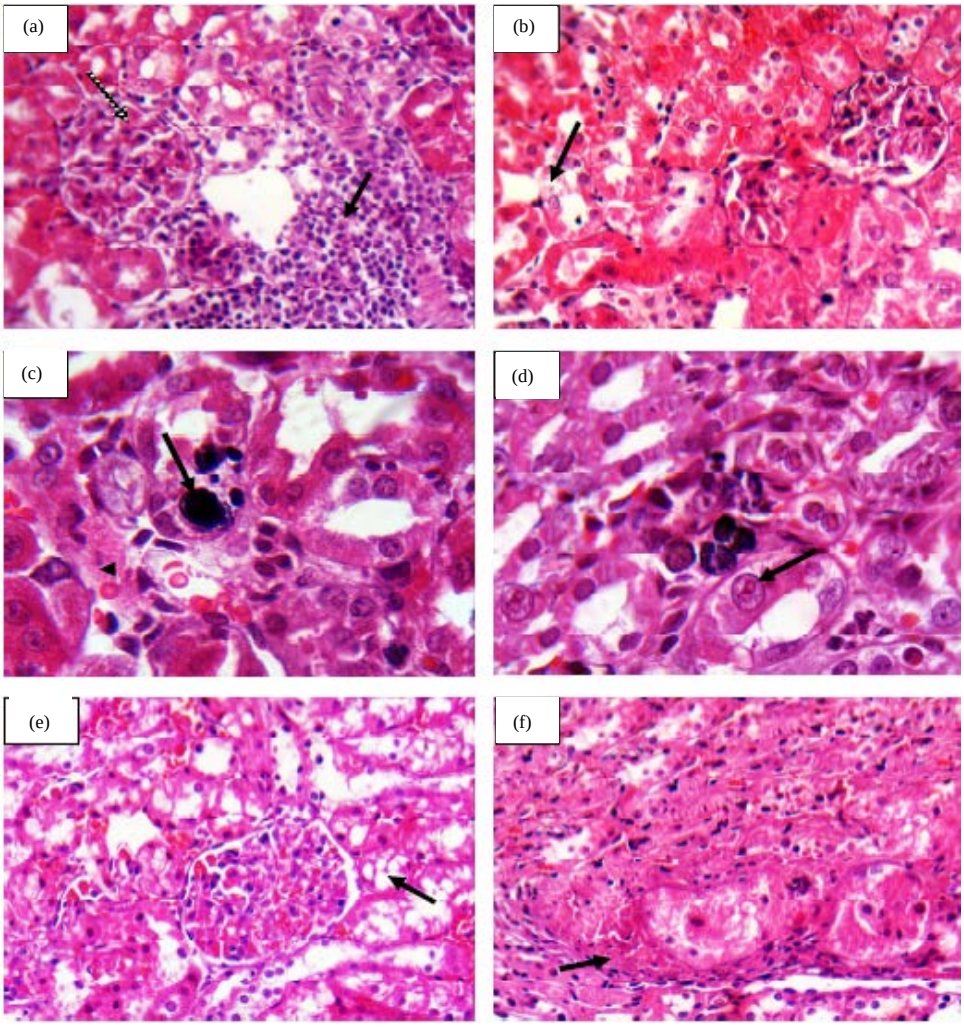


Fig. 1(a-f): Kidney of rats administered either lead acetate (30 mg $kg^{-1}$ b.wt./day) alone in drinking water or in combination with intra peritoneal injection of 54 mg alpha lipoic acid/kg b.wt., for 10 weeks showing, (a) Focal inter tubular mononuclear leukocytic cellular infiltrations mainly lymphocytes (black arrow). Note also, hypercellularity of the glomerular tuft (spotted arrow), (b) Degenerative changes of the lining epithelium of the convoluted tubules in the renal cortex in association with highly granular eosinophilic cytoplasm (arrow), (c) Precipitation of lead pigment either in the lining epithelium of the convoluted tubules or in the lumen of renal tubules (arrow×1000), (d) Intra-nuclear eosinophilic inclusion bodies in the lining epithelium of renal tubules (arrow×1000), (e) Vacuolation of the lining epithelium of some renal tubules (arrow) and (f) Fibrous connective tissue proliferation around the degenerated renal tubules (arrow). H and E stain×400

Table 3: Effect of alpha-lipoic acid on liver and kidney lead residues concentration in normal and lead exposed rats

| | Kidney lead residue (ppm $kg^{-1}$) | | Liver lead residue (ppm $kg^{-1}$) | |
|---|---|---|---|---|
| | Weeks | | Weeks | |
| Animal groups | 8 | 10 | 8 | 10 |
| Control normal | 152.270±14.98[c] | 362.18±29.74[c] | 179.67±4.51[c] | 412.60±22.40[c] |
| Lead acetate | 1363.17±194.38[a] | 1816.00±327.07[a] | 482.70±11.89[a] | 714.25±3.80[a] |
| Lead acetate+α-lipoic acid | 379.340±45.68[b] | 691.63±165.99[b] | 329.20±33.59[b] | 586.60±14.69[b] |

Data are presented as (Mean±S.E), S.E: Standard error, mean values with different superscript letters in the same column are significantly different at ($p \leq 0.05$)

subcapsular space in association with thickening of the glomerular basement membrane. Moreover, focal inter tubular mononuclear leukocytic cellular infiltrations mainly lymphocytes was also detected (Fig. 1a). Occasionally, vacuolation of the glomerular endothelial cells was also observed as well as glomerular fibrosis. Furthermore, the lining epithelium of the convoluted tubules in the renal cortex showed degenerative changes as well as the cytoplasm of the lining epithelial cells of renal tubules was highly granular (Fig. 1b). However, individual epithelial cells were shrunken with pyknosis of the nuclei. Furthermore, inter-tubular hemorrhage was observed in the renal cortex. Interestingly, clumps of amorphous blue staining lead pigment were precipitated in variable quantities in the cytoplasm of the degenerated tubules of both renal cortex and medulla (Fig. 1c). Additionally, intra nuclear eosinophilic inclusion bodies were also observed (Fig. 1d).

Mean while, the microscopical examination of kidneys of rats received lead in combination with alpha-lipoic acid revealed mild pathological changes in comparison to lead administered group only. However, these alterations are represented mainly in mild congestion of the renal blood vessels and inter-tubular capillaries. Furthermore, mild degenerative changes were seen in the lining epithelium of the convoluted tubules in the renal cortex (Fig. 1e). Occasionally, fibrous connective tissue proliferation was demonstrated around the degenerated renal tubules (Fig. 1f). Interestingly, blue staining lead substance was not detected in the cytoplasm of the degenerated tubules of both renal cortex and medulla. Moreover, there were no eosinophilic inclusion bodies seen in the renal tissue of the treated rats.

The liver of rats given lead acetate in drinking water for 10-weeks showed congestion of the portal veins with mild hyperplasia of the billiary epithelium (Fig. 2a). Occasionally, multiple focal areas of lytic necrosis characterized by loss of hepatocytes and replaced by aggregates of mononuclear leukocytic cells mainly lymphocytes and fewer macrophages were also seen (Fig. 2b). Furthermore, apoptotic bodies were noticed in some degenerated hepatocytes (Fig. 2c).

In the meantime, the livers of rats given lead acetate with alpha lipoic acid for 10-weeks showed mild degeneration of hepatocytes characterized by multiple variably sized discrete small vacuoles that distend the cell cytoplasm in association with fibrous connective tissue proliferation around the bile duct was noticed (Fig. 2d).

## DISCUSSION

Lead is known to adversely affect many organs as kidney and liver. Lead intoxicated rats showed significant increase in serum TNF-α, IL-6 and IL-1β concentrations when compared with normal control group. These results came in accordance with the recorded data of Struzynska *et al.*[27], Kasten-Jolly *et al.*[28] and Kumawat *et al.*[29] However, these cytokines were assayed as indicators of inflammation and tissue damage in heart degenerative cells and serum of rats treated with lead[30].

Mohammadi *et al.*[31] also observed that lead administration induced oxidative stress and inflammation with increased TNF-α in liver. The TNF-α is a major mediator of the acute inflammatory response that is generated during many disease states, including infection and inflammation[32]. Accordingly, Hamaguchi *et al.*[33] mentioned that, TNF-α is a pro-inflammatory cytokine secreted by macrophages increasingly during ulcerative stress and inducible nitric oxide expression[34].

In the current study, treatment with alpha-lipoic acid to lead intoxicated rats caused significant decrease serum TNF-α, IL-6 and IL1β concentrations when compared with lead intoxicated group. These results are matched with the findings of Bulut *et al.*[35]. It has been suggested that alpha-lipoic acid may improve endothelial dysfunction via anti-inflammatory and antithrombotic mechanisms[36]. Also, LA supplementation markedly repressed expression of inflammatory genes resulting in down regulation of IL-6 mRNA and associated with reduced plasma levels of the IL-6 protein in chronic leg wound healing[37].

Lead intoxicated rats showed significant increase in kidney tissues L-MDA concentrations and significant decrease in kidney tissues CAT, SOD and GPx activities all over the experimental periods. Nearly similar results were recorded by, El-Nekeety *et al.*[38] and Ponce-Canchihuaman *et al.*[39]. Lakshmi *et al.*[40] suggested that exposure to lead significantly increased malondialdehyde levels and significantly decrease in superoxide dismutase and catalase activities in the liver and kidneys of rats. Furthermore, Ahmed and Hassanein[30] shows that lead intake for 8 weeks caused significant increase in levels of lipid peroxidation as measured by the levels of MDA. Malondialdehyde is the final product of lipid peroxidation and is used to determine lipid peroxidation levels[41] as well as MDA is biomarkers of oxidative stress include products of lipid peroxidation, which is one of the most investigated consequences of ROS-induced damage on lipid membranes[42,43]. It was also reported that Pb increased the level of lipid peroxidation[6]. The activities of glutathione peroxidase (GPx), glutathione-s-transferase (GST), catalase (CAT) and superoxide dismutase (SOD) which are major antioxidant enzymes significantly crashed at both exposure and withdrawal of lead in the liver and the erythrocytes. This is an indication that lead toxicity targets antioxidant enzymes

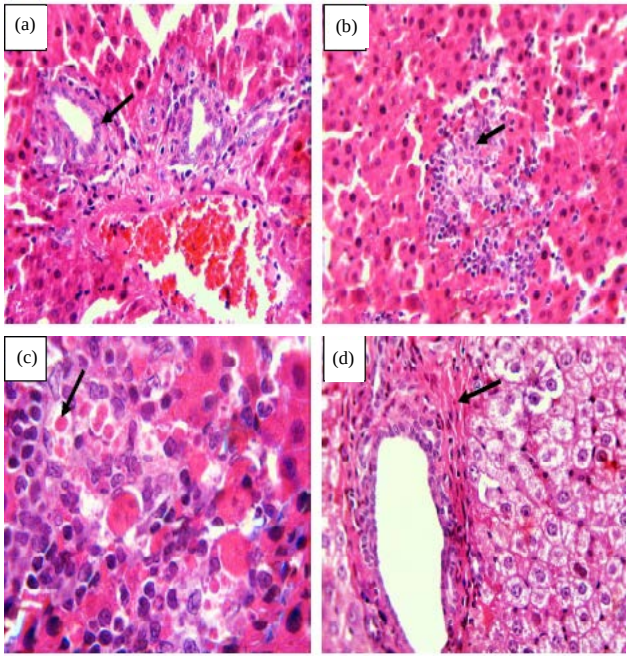


Fig. 2(a-d): Liver of rats administered either lead acetate (30 mg $kg^{-1}$ b.wt./day) alone in drinking water or in combination with intra peritoneal injection of 54 mg alpha lipoic acid /kg b.wt., for 10 weeks showing, (a) Congestion of the portal veins with mild hyperplasia of the billiary epithelium (arrow), (b) Focal area of lytic necrosis characterized by loss of hepatocytes and replaced by aggregates of mononuclear leukocytic cells (arrow), (c) Apoptotic bodies in some degenerated hepatocytes (arrow × 1000) and (d) Hydropic degeneration of hepatocytes in combination with fibrous connective tissue proliferation around the bile duct (arrow). H and E stain × 400

that offer protection against oxidative stress and membrane lipid peroxidation. So, potential toxicity of lead can therefore be ascribed to its inhibiting effects on the antioxidant defense system[44]. These antioxidant enzymes are the primary enzymatic defense against toxic oxygen reduction metabolites and each enzyme has an integral function in free radical modulation. Thus, the accumulated free radical could consume SOD, CAT and GSH-Px in the kidney and liver. Moreover, if the balance between Reactive Oxygen Species (ROS) production and antioxidant defense was disrupted, the enzyme may be exhausted and its concentration may be depleted[45].

In the present study, treatment with alpha-lipoic acid to lead intoxicated male rats caused significant decrease in kidney tissues L-MDA concentration and significant increase in kidney tissues CAT, SOD and GPx activities. These results were similar to that reported by El-Beshbishy *et al.*[46]. Moreover, Sivaprasad *et al.*[47] recorded that ALA had significant ability to prevent lipid peroxidation in the kidneys of lead-exposed rats. However, MDA could be used to estimate lipid peroxidation[48].

Alpha-lipoic acid and DHLA resulted in significant improvement in of thiol capacity of cells via increasing glutathione levels and decreasing MDA levels in lead exposed cells and animals indicating a strong shift of lead induced oxidative stress[49]. Also, LA is known to inhibit the lipid peroxidation process, which could be triggered by ROS and transition metals[50]. The DL-α-lipoic acid is found in human and animal tissue is a latent antioxidant that mainly suppresses lipid peroxidation following oxidative stress and improves the levels of other antioxidants[51,52].

Lead intoxicated rats showed significant increase in kidney tissues DNA fragmentation and caspase-3 activity. These results came in accordance with the recorded data of Liu *et al.*[53], Seddik *et al.*[54] and Liu *et al.*[55]. Similarly, Franco *et al.*[56] demonstrated that, high ROS concentrations contribute to the apoptotic cell death whenever they are generated in the context of the apoptotic process based on labeling of DNA strand breaks in the kidney of rats. Moreover, Liu *et al.*[45] showed that lead induced oxidative DNA damage and apoptosis in rat kidney. Furthermore, Wogniak and Blasiak[57] reported that Pb(II) can directly interact with the DNA molecule, the effect of Pb(II) on the structure of the DNA molecule could be its inhibitory effect on the DNA repair enzymes. Additionally, Dewanjee *et al.*[58] reported that Pb intoxication caused significant DNA fragmentation, which may be due to excess generation of free radicals. Moreover, acute

administration of lead acetate in rats induced toxic effects including changes in hematologic parameters and DNA damage in lymphocytes[59].

Additionally, the caspase-3 activity was involved in the apoptosis pathway induced by Pb[29,60]. The caspase-3 has a central role in this cascade and is known to activate cytoplasmic DNase, which subsequently migrates to the nucleus and fragments the DNA[61]. Therefore, DNA fragmentation-particularly when it is inter-nucleosomal is one of the gold standards for detection of apoptosis[62]. Furthermore, caspase-3 is known to be the main effector protein common to the intrinsic and extrinsic pathways of apoptosis and that ROS overproduction is effectively involved in both mechanisms[63].

Lead could induce DNA damage and apoptosis in PC 12 cells, accompanied by an up regulation of bax and down regulation of Bcl2[64]. It is associated with DNA damage through base pair mutation, deletion, or oxygen radical attack on DNA[65]. Apoptosis, programmed death of cells through DNA fragmentation, cell shrinkage and dilation of endoplasmic reticulum are normally followed by cell degeneration and the formation of membrane vesicles, called apoptosis bodies[66].

Moreover, DNA fragmentation observed herein by the comet assay was also reported for humans exposed to Pb(II)[67]. Such evidence may be due to a direct effect of Pb(II) on the DNA structure, oxidative mechanisms[68] or indirectly due to another mechanism involving the activation of caspases in the process of cell death[69]. The Pb can induce DNA injury in the kidney and these effects were shown to be associated with ROS formation resulting in caspase-3 dependent apoptosis[53].

Treatment with alpha-lipoic acid to lead intoxicated rats caused a significant decrease in kidney tissues DNA fragmentation and caspase-3 activity when compared with lead exposed group. These results are nearly similar with Aoyama *et al.*[70] reported that, lipoic acid inhibit apoptosis of cell by means of its antioxidant activity. Similarly, Suh *et al.*[71] showed that dietary supplementation of LA 0.2% (wt/wt) for 2 weeks markedly reduced oxidative DNA damage in cardiac tissue of old rats. Also, Konuk *et al.*[72] demonstrated that LA has a protective effect on the liver sub-chronic thinner-addicted rats. The DNA damage increased in the sub-chronic thinner inhalation group. However, the damage was significantly lowered in lipoic acid treated rats group. On other hand, ALA intake to mice significantly decreased the serum caspase-3 activity[46].

Lipoic acid and its reduced form DHLA have been shown to inhibit proliferation and induce apoptosis of several cancer and transformed cell lines[73]. On the other hand, it has been also shown that LA inhibits endothelial cell proliferation and apoptosis[74]. Similarly, it was demonstrated that application of the antioxidant LA in animal and cell culture models decreases oxidative stress and supports the endogenous antioxidant systems potently and apoptosis-related cell death in tissues exposed to oxidant injury[75,76].

A significant increase in kidney tissues 8-OhdG, NF-κB P65 concentration and Cox-2 activity were observed in lead exposed rats (Table 3). These results came in accordance with the recorded data of Liu *et al.*[45], who reported that the level of 8-OHdG was markedly increased in the kidney of Pb-treated rats, suggesting that DNA is a common target of ROS induced by Pb in kidney. Also, Galazyn-Sidorczuk *et al.*[77] demonstrated that cadmium, arsenic trioxide, methyl mercury and ferric nitrilotriacetate (Fe-NTA) can induce increase of 8-OHdG levels in the kidney. More than 100 oxidative products of DNA have been identified, the best known being of 8-hydroxyguanine (8-OH-G)[78]. The 8-OhdG is one of such important oxidative DNA lesions formed by the oxidation of the C-8 position of 2-deoxyguanosine, which has commonly been used as a biomarker of oxidative DNA damage[79].

On the other hand, Rodriguez-Iturbe *et al.*[80] reported that 4 months of low-dose lead exposure induces infiltration of lymphocytes and macrophages, increased numbers of proximal tubular cells and infiltrating cells showing intranuclear p65 NF-κB and angiotensin II expression in tubular and infiltrating cells. Moreover, Chen and Shi[81] show that varieties of toxic metals are able to affect the activation or activity of NF-κB. It is a mammalian transcriptional activator known to be involved in the inducible expression of a variety of genes, particularly those involved in cellular proliferative, survival and anti-apoptotic processes[82]. The NF-κB can be activated by a variety of ROS that cause oxidative stress[83]. It has been realized for decades that oxidative stress is the major effect of toxic metals on cellular events[84].

Meanwhile, Courtois *et al.*[85] reported that lead exposure increased COX-2 expression in the arterial wall; the increased superoxide anion generation induced by lead stimulated the expression of COX-2 protein. Also, Chou *et al.*[86] demonstrated that lead has been reported to induce Cyclooxygenase-2 gene expression by epidermal growth factor receptor/nuclear factor-kappa B signaling carcinoma cells. Moreover, Kaushik *et al.*[87] showed that the magnitude of pro-inflammatory cytokine secretion and the increased production of COX-2 in response to Pb suggested the involvement of NF-kB pathway as this transcription factor is implicated in the transcriptional regulation of these cytochemokines. It is already known that NF-κB can bind to

the promoter elements of TNF-α, MCP-1, IL-6 as well as COX-2. Furthermore, Kumawat *et al.*[29] reported that a significant increase in the expression of COX-2 was observed in the Pb-treated group when compared with control. Additionally, Omobowale *et al.*[44] recorded that significant expression of COX-2 in rats exposed to lead compared to the control. Also, Ahmed and Hassanein[30] demonstrated that the heart tissue revealed positive Cox-2 expression in Pb-treated group. Cyclooxygenase (COX) is the rate-limiting enzyme in the biosynthesis of prostaglandins. The COX-2 is an early response gene and induced by many pro-inflammatory cytokines, including endotoxin, cytokines, mitogens and other stimuli, whereas COX-1 is constitutively expressed in most of the tissues[88].

In the current study, treatment with alpha-lipoic acid to lead intoxicated male rats, significantly reduced the elevated 8-OhdG, NF-κBp65 level and COX-2 activity in lead intoxicated male rats all over the periods of the experiment. These results came in accordance with the recorded data of Sena *et al.*[89] who observed that 8-OHdG levels was fully reversed with alpha-LA treatment. Kara *et al.*[15] reported that LA inhibits NF-κB activation and adhesion molecule expression in human aortic endothelial cells. As well, LA metabolites have been shown to have anti-inflammatory and antioxidant effects[90]. On other hand, Li *et al.*[91] reported that ALA markedly inhibited radiation or $H_2O_2$-induced COX-2 upregulation. The anti-inflammatory effect of LA likely resides in the fact that COX-2 and phospholipase A2 the main source of the substrate for prostaglandin biosynthesis are both inhibited by lipoic acid[92-94].

The inhibition of apoptosis by LA was paralleled by reduction of NF-kB, while ALA was shown to attenuate the DNA-binding activity of NF-kB in numerous cell types[95,96] and to inhibit TNF-α-induced NF-κB activation[97,98]. Thus, the LA-induced NF- κB inhibition may contribute primarily to suppress the inflammatory process inhibiting the apoptosis, cell proliferation, expression of ROS and many other inflammatory genes (e.g., IL-1, IL-6, TNF-α), which are contributing factors in healing failure.

The obtained results revealed that kidney and liver lead residues concentrations increased significantly in lead exposed rats when compared with normal control. Similarly, Alcaraz-Contreras *et al.*[99] who reported that lead exposure caused a significant increase in its levels in blood, brain, liver, kidney and bone samples compared with samples from controls. The high concentration of lead in different tissues has been associated with oxidative stress, which might be responsible, at least in part, for lead's toxic effects. Also, Aziz *et al.*[100] showed that the high increase of lead content was observed in the kidneys and livers of rats. Similarly, Liu *et al.*[55] recorded that the Pb levels in blood and kidney of Pb-treated rats are significantly higher than those of control rats. Moreover, previous researchers also observed that the highest concentration of lead is found in the kidney. Furthermore, Rezk and Abdel-Rahman[101] demonstrated that highest retention of lead was observed in kidney along the experimental time and the lowest retention was in the lung.

Lead appears within and among soft tissues where the highest concentration of lead seems to accumulate specially in those organs and tissues with the highest mitochondrial activity, these include the kidney renal tubules. The administration of lead had a greater influence on increased kidney lead levels and urine lead levels[102]. Also, the function of oxidative damage in Pb-and Cd-induced changes in steroidogenesis in the liver and kidney[7].

Meanwhile, in the present study, treatment with alpha-lipoic acid to lead intoxicated male rats resulted in significant decrease in kidney and liver lead residues concentrations when compared with lead exposed group. These results came in accordance with the recorded data of Osfor *et al.*[103] who reported that Alpha Lipoic Acid (ALA) decrease lead levels in serum and kidney tissue of lead intoxicated rats compared to the control rats. Moreover, Pande and Flora[104] observed that treatment with α-lipoic acid led to decreased lead burden and lipid peroxide formation. These beneficial effects might be due to the chelation of lead by the thiol chelators and the antioxidant action of α-lipoic acid. Antioxidant LA would repair the damaged tissues effectively and improve the thiol status. Also, LA as a potent antioxidant not only scavenges free radicals but also raises the intracellular level of antioxidants by recycling them and chelates heavy metals to prevent free radical generation. Moreover, LA antioxidant role involves protecting cells from damage by preventing the destruction of lipids in cell membranes. Unlike other antioxidants LA is soluble in both water and fat because of these unique antioxidant functions, lipoic acid is known as the universal antioxidant[105]. Furthermore, LA/DHLA chelating lead from the various tissues and enhancing its elimination thereby preventing the toxic effects posed by the metal[106].

In the current study, it is clear that lead intoxication is adversely affect liver and kidneys. The most prominent pathological alterations in lead exposed kidney degeneration of the tubular epithelium, intranuclear eosinophilic inclusions as well as hyperplasia of the Bowman's capsule with interstitial mononuclear leukocytic cellular infiltrations. The pathological changes demonstrated in liver and kidney that could be attributed to oxidative damage of cell membranes via the

accumulation of oxidant metabolites as well as direct or indirect inhibition of antioxidant enzymes induced by lead[80]. Additionally, the necrotic changes observed in renal and hepatic tissues in the present work may be due to oxidative stress induced by accumulation of lead in kidney and liver. These findings come in accordance with the highly significant increase in lead residues in liver and kidney tissues in lead intoxicated rats. It has been found that lead was found to be localized in the cytoplasm of capillary endothelium that could clarify the appearance of hemorrhagic areas in renal and hepatic tissues. Moreover, the other lesions resulted from lead intoxication could be due to endothelial damage and circulatory deficiency[107]. Furthermore, constant intranuclear eosinophilic inclusions were observed in the lining epithelium of renal tubules. These findings are agreed with that recorded by Jarrar[108]. However, lead inclusions may represent accumulation of both extracellular and intracellular materials which indicate disturbance in the cellular metabolism and/or alterations in the nuclear membranes[109]. Generally, the tubular changes in lead toxicity occur earlier than glomerular and interstitial tissues. These early changes represented mainly in development of pathognomonic intranuclear inclusions in the renal tubular cells. However, lead intoxication resulting in pathological changes in the renal cortex which could play a principle role in renal dysfunction. Furthermore, apoptosis of hepatocytes was demonstrated in lead intoxicated rats.

In the present study, LA is significantly improved the histological changes in renal and hepatic tissues resulted from lead intoxication. The LA is able to protect cells from damage by preventing the destruction of lipids in cell membrane[49]. On the other hand, LA has a potent antioxidant effect against lead intoxication via increasing the intracellular level of antioxidants by recycling them and chelates heavy metals to prevent free radicals generation. Additionally, LA inhibits apoptosis of cells by its antioxidant activity[70], these findings are matched with the results of the existing study. However, the histopathological studies in the kidney and liver of rats also supported that alpha-lipoic acid markedly reduced the Pb induced pathological changes and preserved the normal histological architecture of the kidney and liver tissues.

## CONCLUSION

It could be concluded that the potential ameliorating effect of alpha-lipoic acid as powerful agents and may be useful as an antioxidants in combating free radical-induced oxidative stress and tissue injury that is a result of lead toxicity. Also, alpha-lipoic acids have a protective antioxidant and anti-inflammatory effects as it inhibit NF-κB P65 , COX-2 activity and also inhibit TNF-α induced NF-κB P65 activation and could be also applicable as a cytoprotective against oxidative stress of tissue damage mediated by lead intoxication.

Thus, LA administration in intoxicated rats induced NF-κB P65 inhibition may contribute primarily suppress the inflammatory process inhibiting the apoptosis, ROS and many other inflammatory markers (IL-6, IL-1β and TNF-α) which are contributing factors in organ failure as well as improve the pathological alterations in renal and hepatic tissues. Therefore, we recommended that alpha-lipoic acid is very essential and should be used with safe therapeutic dose which may treat the undesirable and dangerous toxic effects during heavy metals exposure.

## REFERENCES


1. Zbakh, H. and A. El Abbassi, 2012. Potential use of olive mill wastewater in the preparation of functional beverages: A review. J. Funct. Foods, 4: 53-65.
2. Patrick, L., 2006. Lead toxicity, a review of the literature. Part 1: Exposure, evaluation and treatment. Altern. Med. Rev., 11: 2-22.
3. Campbell, J.R., R.N. Rosier, L. Novotny and J.E. Puzas, 2004. The association between environmental lead exposure and bone density in children. Environ. Health. Perspect., 112: 1200-1203.
4. Gurer-Orhan, H., H.U. Sabir and H. Oezguenes, 2004. Correlation between clinical indicators of lead poisoning and oxidative stress parameters in controls and lead-exposed workers. Toxicology, 195: 147-154.
5. Waters, M., S. Stasiewicz, B.A. Merrick, K. Tomer and P. Bushel *et al*., 2008. CEBS-chemical effects in biological systems: A public data repository integrating study design and toxicity data with microarray and proteomics data. Nucleic Acids Res., 36: D892-D900.
6. Upasani, C.D., A. Khera and R. Balaraman, 2001. Effect of lead with vitamin E, C, or Spirulina on malondialdehyde, conjugated dienes and hydroperoxides in rats. Ind. J. Exp. Biol., 39: 70-74.
7. Dai, S., Z. Yin, G. Yuan, H. Lu and R. Jia *et al*., 2013. Quantification of metallothionein on the liver and kidney of rats by subchronic lead and cadmium in combination. Environ. Toxicol. Pharmacol., 36: 1207-1216.
8. Sujatha, K., C. Srilatha, Y. Anjanyulu and P. Amarawathi, 2011. Lead acetate induced neurotoxicity in Wistar albino rats: A pathological, immunological and ultrastructural studies. J. Pharm. Biosci., 2: 459-462.
9. Dev, P.R., D. Swarup and S.K. Dwivedi, 1991. Some renal-function tests in experimental lead toxicity in goats. Indian Vet. J., 68: 1163-1167.

10. Flora, S.J.S., 2002. Nutritional components modify metal absorption, toxic response and chelation therapy. J. Nutr. Environ. Med., 12: 53-67.
11. May, J.M., Z.C. Qu and D.J. Nelson, 2007. Uptake and reduction of α-lipoic acid by human erythrocytes. Clin. Biochem., 40: 1135-1142.
12. Shay, K.P., R.F. Moreau, E.J. Smith, A.R. Smith and T.M. Hagen, 2009. Alpha-lipoic acid as a dietary supplement: Molecular mechanisms and therapeutic potential. Biochimica Biophysica Acta-General Subjects, 1790: 1149-1160.
13. Caylak, E., M. Aytekin and I. Halifeoglu, 2008. Antioxidant effects of methionine, α-lipoic acid, *N*-acetylcysteine and homocysteine on lead-induced oxidative stress to erythrocytes in rats. Exp. Toxicol. Pathol., 60: 289-294.
14. Winiarska, K., D. Malinska, K. Szymanski, M. Dudziak and J. Bryla, 2008. Lipoic acid ameliorates oxidative stress and renal injury in alloxan diabetic rabbits. Biochimie, 90: 450-459.
15. Kara, A., S. Akman, T. Demirci and T. Arabaci, 2013. Influence of alpha lipoic acid on epithelial apoptosis in experimental periodontitis. Turk. J. Med. Sci., 43: 747-755.
16. Gruzman, A., A. Hidmi, J. Katzhendler, A. Haj-Yehie and S. Sasson, 2004. Synthesis and characterization of new and potent A-lipoic acid derivatives. Bioorg. Med. Chem., 12: 1183-1190.
17. Al-Ghais, S.M., 1995. Heavy metal concentration in the tissues of Sparus Serba (Forkal, 1975) from the United Arab Emirates. Bull. Environ. Contam. Toxicol., 55: 581-581.
18. Dray, T. and S. Walling, 1976. Conleton's Histopathological Technique. University Press, London, Oxford, pp: 114-118.
19. Beyaert, R. and W. Fiers, 1998. Tumor Necrosis Factor and Lymphotoxin. In: Cytokines, Mire-Sluis, A.R. and R. Thorpe (Eds.). Academic Press, San Diego, California, pp: 335-360.
20. Chan, D.W.Y. and M.T. Perlstein, 1987. Immunoassay: A Practical Guide. Academic Press, New York, pp: 71.
21. Esterbauer, H., K.H. Cheeseman, M.U. Dianzani, G. Poli and T.F. Slater, 1982. Separation and characterization of the aldehydic products of lipid peroxidation stimulated by ADP-Fe2+ in rat liver microsomes. Biochem. J., 208: 129-140.
22. Sinha, A.K., 1972. Colorimetric assay of catalase. Anal. Biochem., 47: 389-394.
23. Packer, L. and A.N. Glazer, 1990. Oxygen Radicals in Biological Systems Part B: Oxygen Radicals and Antioxidants (Methods in Enzymology, Volume 186). Academic Press Inc., New York, USA., ISBN: 978-0-12-182087-9, pp: 251.
24. Gross, R.T., R. Bracci, N. Rudolph, E. Schroeder and J.A. Kochen, 1967. Hydrogen peroxide toxicity and detoxification in the erythrocytes of newborn infants. Blood, 29: 481-493.
25. Necheles, T.F., T.A. Boles and D.M. Allen, 1968. Erythrocyte glutathione-peroxidase deficiencyand hemolytic disease of the newborn infant. J. Pediat., 72: 319-324.
26. Shi, B., U. de Girolami, J. He, S. Wang, A. Lorenzo, J. Busciglio and D. Gabuzda, 1996. Apoptosis induced by HIV-1 infection of the central nervous system. J. Clin. Invest., 98: 1979-1990.
27. Struzynska, L., B. Dabrowska-Bouta, K. Koza and G. Sulkowski, 2007. Inflammation-like glial response in lead-exposed immature rat brain. Toxicol. Sci., 95: 156-162.
28. Kasten-Jolly, J., Y. Heo and D.A. Lawrence, 2011. Central nervous system cytokine gene expression: Modulation by lead. J. Biochem. Mol. Toxicol., 25: 41-54.
29. Kumawat, K.L., D.K. Kaushik, P. Goswami and A. Basu, 2014. Acute exposure to lead acetate activates microglia and induces subsequent bystander neuronal death via caspase-3 activation. NeuroToxicology, 41: 143-153.
30. Ahmed, M.A. and K.M.A. Hassanein, 2013. Cardio protective effects of *Nigella sativa* oil on lead induced cardio toxicity: Anti inflammatory and antioxidant mechanism. J. Physiol. Pathophysiol., 4: 72-80.
31. Mohammadi, M., R. Ghaznavi, R. Keyhanmanesh, H.R. Sadeghipour, R. Naderi and H. Mohammadi, 2014. Caloric restriction prevents lead-induced oxidative stress and inflammation in rat liver. Scient. World J. 10.1155/2014/821524
32. Takeuchi, T., S. Miura, L. Wang, K. Uehara and M. Mizumori *et al*., 2002. Nuclear factor-kappaB and TNF-alpha mediate gastric ulceration induced by phorbol myristate acetate. Dig Dis. Sci., 47: 2070-2078.
33. Hamaguchi, M., T. Watanabe, K. Higuchi, K. Tominaga, Y. Fujiwara and T. Arakawa, 2001. Mechanisms and roles of neutrophil infiltration in stress-induced gastric injury in rats. Dig. Dis. Sci., 46: 2708-2715.
34. Calatayud, S., D. Barrachina and J.V. Esplugues, 2001. Nitric oxide: Relation to integrity, injury and healing of the gastric mucosa. Microsc. Res. Tech., 53: 325-335.
35. Bulut, N.E., E. Ozkan, O. Ekinci, E. Dulundu and U. Topaloglu *et al*., 2011. Beneficial effects of alpha lipoic acid on cerulein-induced experimental acute pancreatitis in rats. Turk. J. Trauma Emergency Surg., 17: 383-389.
36. Sola, S., M.Q.S. Mir, F.A. Cheema, N. Khan-Merchant and R.G. Menon *et al*., 2005. Irbesartan and lipoic acid improve endothelial function and reduce markers of inflammation in the metabolic syndrome: Results of the irbesartan and lipoic acid in endothelial dysfunction (ISLAND) study. Circulation, 111: 343-348.
37. Nasole, E., C. Nicoletti, Z.J. Yang, A. Girelli and A. Rubini *et al*., 2014. Effects of alpha lipoic acid and its R+ enantiomer supplemented to hyperbaric oxygen therapy on interleukin-6, TNF-α and EGF production in chronic leg wound healing. J. Enzyme Inhib. Med. Chem., 29: 297-302.
38. El-Nekeety, A.A., A.A. El-Kady, M.S. Soliman, N.S. Hassan and M.A. Abdel-Wahhab, 2009. Protective effect of *Aquilegia vulgaris* (L.) against lead acetate-induced oxidative stress in rats. Food Chem. Toxicol., 47: 2209-2215.

39. Ponce-Canchihuaman, J.C., O. Perez-Mendez, Hernandez-Munoz, R., P.V. Torres-Duran and M.A. Juarez-Oropeza, 2010. Protective effects of *Spirulina maxima* on hyperlipidemia and oxidative-stress induced by lead acetate in the liver and kidney. Lipid Health Dis., Vol. 9. 10.1186/1476-511X-9-35
40. Lakshmi, B.V.S., M. Sudhakar and M. Aparna, 2013. Protective potential of Black grapes against lead induced oxidative stress in rats. Environ. Toxicol. Pharmacol., 35: 361-368.
41. Johansen, J.S., A.K. Harris, D.J. Rychly and A. Ergul, 2005. Oxidative stress and the use of antioxidants in diabetes: Linking basic science to clinical practice. Cardiovasc. Diabetol., Vol. 4. 10.1186/1475-2840-4-5
42. Flora, G., D. Gupta and A. Tiwari, 2012. Toxicity of lead: A review with recent updates. Interdiscip. Toxicol., 5: 47-58.
43. Khan, D.A., S. Qayyum, S. Saleem, F.A. Khan, 2008. Lead-induced oxidative stress adversely affects health of the occupational workers. Toxicol. Ind. Health, 24: 611-618.
44. Omobowale, T.O., A.A. Oyagbemi, A.S. Akinrinde, A.B. Saba, O.T. Daramola, B.S. Ogunpolu and J.O. Olopade, 2014. Failure of recovery from lead induced hepatoxicity and disruption of erythrocyte antioxidant defence system in Wistar rats. Environ. Toxicol. Pharmacol., 37: 1202-1211.
45. Liu, C.M., J.Q. Ma and Y.Z. Sun, 2010. Quercetin protects the rat kidney against oxidative stress-mediated DNA damage and apoptosis induced by lead. Environ. Toxicol. Pharmacol., 30: 264-271.
46. El-Beshbishy, H.A., S.A. Bahashwan, H.A.A. Aly and H.A. Fakher, 2011. Abrogation of cisplatin-induced nephrotoxicity in mice by alpha lipoic acid through ameliorating oxidative stress and enhancing gene expression of antioxidant enzymes. Eur. J. Pharmacol., 668: 278-284.
47. Sivaprasad, R., M. Nagaraj and P. Varalakshmi, 2002. Lipoic acid in combination with a chelator ameliorates lead-induced peroxidative damages in rat kidney. Arch. Toxicol., 76: 437-441.
48. Abdel-Aal, K.M. and M.R.H. Abeer, 2008. Therapeutic efficacy of alpha lipoic acid in combination with succimer against lead-induced oxidative stress, hepatotoxicity and nephrotoxicity in rats. Assuit Univ. Bull. Environ. Res., 11: 87-99.
49. Gurer, H., H. Ozgunes, S. Oztezcan and N. Ercal, 1999. Antioxidant role of α-lipoic acid in lead toxicity. Free Radical Biol. Med., 27: 75-81.
50. Gurer, H. and N. Ercal, 2000. Can antioxidants be beneficial in the treatment of lead poisoning?. Free Radic. Biol. Med., 29: 927-945.
51. Arivazhagan, P., K. Ramanathan and C. Panneerselvam, 2001. Effect of DL-α-lipoic acid on the status of lipid peroxidation and antioxidants in mitochondria of aged rats. J. Nutr. Biochem., 12: 2-6.
52. Arivazhagan, P., T. Thilakavathy, K. Ramanathan, S. Kumaran and C. Panneerselvam, 2002. Effect of DL-α-lipoic acid on the status of lipid peroxidation and protein oxidation in various brain regions of aged rats. J. Nutri. Biochem., 13: 619-624.
53. Liu, C.M., Y.L. Zheng, J. Lu, Z.F. Zhang, S.H. Fan, D.M. Wu and J.Q. Ma, 2010. Quercetin protects rat liver against lead-induced oxidative stress and apoptosis. Environ. Toxicol. Pharmacol., 29: 158-166.
54. Seddik, L., T.M. Bah, A. Aoues, M. Slimani and M. Benderdour, 2011. Elucidation of mechanisms underlying the protective effects of olive leaf extract against lead-induced neurotoxicity in Wistar rats. J. Toxicol. Sci., 36: 797-809.
55. Liu, M.C., X.Q. Liu, W. Wang, X.F. Shen and H.L. Che *et al*., 2012. Involvement of microglia activation in the lead induced long-term potentiation impairment. PLoS ONE, Vol. 7. 10.1371/journal.pone.0043924
56. Franco, R., R. Sanchez-Olea, E.M. Reyes-Reyes and M.I. Panayiotidis, 2009. Environmental toxicity, oxidative stress and apoptosis: Menage a trois. Mutat. Res./Genet. Toxicol. Environ. Mutagen., 674: 3-22.
57. Wogniak, K. and J. Blasiak, 2003. *In vitro* genotoxicity of lead acetate: Induction of single and double DNA strand breaks and DNA-protein cross-links. Mutat. Res. Genet. Toxicol. Environ. Mutagen., 535: 127-139.
58. Dewanjee, S., R. Sahu, S. Karmakar and M. Gangopadhyay, 2013. Toxic effects of lead exposure in Wistar rats: Involvement of oxidative stress and the beneficial role of edible jute (*Corchorus olitorius*) leaves. Food Chem. Toxicol., 55: 78-91.
59. Ibrahim, N.M., E.A. Eweis, H.S. El-Beltagi and Y.E. Abdel-Mobdy, 2011. The effect of lead acetate toxicity on experimental male albino rat. Biol. Trace Elem. Res., 144: 1120-1132.
60. Pulido, M.D. and A.R. Parrish, 2003. Metal-induced apoptosis: Mechanisms. Mutat. Res./Fundam. Mol. Mech. Mutagen., 533: 227-241.
61. Dribben, W.H., C.E. Creeley and N. Farber, 2011. Low-level lead exposure triggers neuronal apoptosis in the developing mouse brain. Neurotoxicol. Teratol., 33: 473-480.
62. Goel, R.K., K. Sairam, M.D. Babu, I.A. Tavares and A. Raman, 2003. *In vitro* evaluation of *Bacopa monniera* on anti-*Helicobacter pylori* activity and accumulation of prostaglandins. Phytomedicine, 10: 523-527.
63. Astiz, M., M.J.T. de Alaniz and C.A. Marra, 2009. Effect of pesticides on cell survival in liver and brain rat tissues. Ecotoxicol. Environ. Saf., 72: 2025-2032.
64. Xu, J., L.D. Ji and L.H. Xu, 2006. Lead-induced apoptosis in PC 12 cells: Involvement of p53, Bcl-2 family and caspase-3. Toxicol. Lett., 166: 160-167.
65. Shalan, M.G., M.S. Mostafa, M.M. Hassouna, S.E.H. El-Nabi and A. El-Refaie, 2005. Amelioration of lead toxicity on rat liver with vitamin C and silymarin supplements. Toxicology, 206: 1-15.

66. Ismail, I.F., S. Golbabapour, P. Hassandarvish, M. Hajrezaie and N.A. Majid *et al*., 2012. Gastroprotective activity of polygonum chinense aqueous leaf extract on ethanol-induced hemorrhagic mucosal lesions in rats. Evid. Based Complement Alternat. Med. 10.1155/2012/404012
67. Danadevi, K., R. Rozati, B.S. Banu, P.H. Rao and P. Grover, 2003. DNA damage in workers exposed to lead using comet assay. Toxicology, 187: 183-193.
68. Stohs, S.J. and D. Bagchi, 1995. Oxidative mechanisms in the toxicity of metal ions. Free Radic. Biol. Med., 18: 321-336.
69. Saleh, A.M., C. Vijayasarathy, L. Masoud, L. Kumar, A. Shahin and A. Kambal, 2003. Paraoxon induces apoptosis in EL4 cells via activation of mitochondrial pathways. Toxicol. Applied Pharmacol., 190: 47-57.
70. Aoyama, S., Y. Okimura, H. Fujita, E.F. Sato and T. Umegaki *et al*., 2006. Stimulation of membrane permeability transition by alpha-lipoic acid and its biochemical characteristics. Physiol. Chem. Phys. Med. NMR, 38: 1-20.
71. Suh, J.H., E.T. Shigeno, J.D. Morrow, B. Cox, A.E. Rocha, B. Frei and T.M. Hagen, 2001. Oxidative stress in the aging rat heart is reversed by dietary supplementation with (R)-α-lipoic acid. FASEB J., 15: 700-706.
72. Konuk, M., T. Sahin, I.H. Cigerci, A.F. Fidan and S.E. Korcan, 2012. Effects of α-lipoic acid on DNA damage, protein oxidation, lipid peroxidation, and some biochemical parameters in subchronic thinner-addicted rats. Turk. J. Biol., 36: 702-710.
73. Shi, D.Y., H.L. Liu, J.S. Stern, P.Z. Yu and S.L. Liu, 2008. Alpha-lipoic acid induces apoptosis in hepatoma cells via the PTEN/Akt pathway. FEBS Lett., 582: 1667-1671.
74. Artwohl, M., K. Muth, K. Kosulin, R. de Martin and T. Holzenbein *et al*., 2007. R-(+)-α-lipoic acid inhibits endothelial cell apoptosis and proliferation: Involvement of Akt and retinoblastoma protein/E2F-1. Am. J. Physiol.-Endocrinol. Metab., 293: E681-E689.
75. Dincer, Y., A. Telci, R. Kayali, I.A. Yilmaz, U. Cakatay and T. Akcay, 2002. Effect of α-lipoic acid on lipid peroxidation and anti-oxidant enzyme activities in diabetic rats. Clin. Exp. Pharmacol. Physiol., 29: 281-284.
76. Vincent, A.M., L.L. McLean, C. Backus and E.L. Feldman, 2005. Short-term hyperglycemia produces oxidative damage and apoptosis in neurons. FASEB J., 19: 638-640.
77. Galazyn-Sidorczuk, M., M.M. Brzoska, M. Jurczuk and J. Moniuszko-Jakoniuk, 2009. Oxidative damage to proteins and DNA in rats exposed to cadmium and/or ethanol. Chem.-Biol. Interact., 180: 31-38.
78. Dizdaroglu, M., P. Jaruga, M. Birincioglu and H. Rodriguez, 2002. Free radical-induced damage to DNA: Mechanisms and measurement. Free Radical Biol. Med., 32: 1102-1115.
79. Chen, H., G. Chu, Z. Cao, J. Liang, J. Lu and G. Zhou, 2010. Magnetic bead-based approach to monitoring of cigarette smoke-induced DNA oxidation damage and screening of natural protective compounds. Talanta, 80: 1216-1221.
80. Rodriguez-Iturbe, B., R.K. Sindhu, Y. Quiroz and N.D. Vaziri, 2005. Chronic exposure to low doses of lead results in renal infiltration of immune cells, NF-κB activation and overexpression of tubulointerstitial angiotensin II. Antioxidants Redox Signaling, 7: 1269-1274.
81. Chen, F. and X. Shi, 2002. Signaling from toxic metals to NF-kappaB and beyond: Not just a matter of reactive oxygen species. Environ. Health Perspect., 110: 807-811.
82. Chen, Q., N. Takeyama, G. Brady, A.J. Watson and C. Dive, 1998. Blood cells with reduced mitochondrial membrane potential and cytosolic cytochrome C can survive and maintain clonogenicity given appropriate signals to suppress apoptosis. Blood, 92: 4545-4553.
83. Chaturvedi, M.M., A. Mukhopadhyay and B.B. Aggarwal, 2000. Assay for redox-sensitive transcription factor. Methods Enzymol., 319: 585-602.
84. Salnikow, K., W. Su, M.V. Blagosklonny and M. Costa, 2000. Carcinogenic metals induce hypoxia-inducible factor-stimulated transcription by reactive oxygen species-independent mechanism. Cancer Res., 60: 3375-3378.
85. Courtois, E., M. Marques, A. Barrientos, S. Casado and A. Lopez-Farre, 2003. Lead-induced downregulation of soluble guanylate cyclase in isolated rat aortic segments mediated by reactive oxygen species and cyclooxygenase-2. J. Am. Soc. Nephrol., 14: 1464-1470.
86. Chou, Y.H., P.Y. Woon, W.C. Huang, R. Shiurba and Y.T. Tsai *et al*., 2011. Divalent lead cations induce *cyclooxygenase*-2 gene expression by epidermal growth factor receptor/nuclear factor-kappa B signaling in A431carcinoma cells. Toxicol. Lett., 203: 147-153.
87. Kaushik, D.K., M. Gupta, S. Das and A. Basu, 2010. Kruppel-like factor 4, a novel transcription factor regulates microglial activation and subsequent neuroinflammation. J. Neuroinflamm., Vol. 7. 10.1186/1742-2094-7-68
88. Wu, G.F., J. Luo, J.S. Rana, R. Laham, F.W. Sellke and J. Li, 2006. Involvement of COX-2 in VEGF-induced angiogenesis via P38 and JNK pathways in vascular endothelial cells. Cardiovascul. Res., 69: 512-519.
89. Sena, C.M., E. Nunes, T. Louro, T. Proenca, R. Fernandes, M.R. Boarder and R.M. Seica, 2008. Effects of α-lipoic acid on endothelial function in aged diabetic and high-fat fed rats. Br. J. Pharmacol., 153: 894-906.
90. Kwiecien, B., M. Dudek, A. Bilska-Wilkosz, J. Knutelska and M. Bednarski *et al*., 2013. *In vivo* anti-inflammatory activity of lipoic acid derivatives in mice. Postepy Higieny Medycyny Doswiadczalnej, 67: 331-338.

91. Li, L., K.K. Steinauer, A.J. Dirks, B. Husbeck, I. Gibbs and S.J. Knox, 2003. Radiation-induced cyclooxygenase 2 up-regulation is dependent on redox status in prostate cancer cells. Radiat. Res., 160: 617-621.
92. Ha, H., J.H. Lee, H.N. Kim, H.M. Kim and H.B. Kwak *et al*., 2006. α-lipoic acid inhibits inflammatory bone resorption by suppressing prostaglandin $E_2$ synthesis. J. Immunol., 176: 111-117.
93. Jameel, N.M., M.A. Shekhar and B.S. Vishwanath, 2006. α-Lipoic acid: An inhibitor of secretory phospholipase $A_2$ with anti-inflammatory activity. Life Sci., 80: 146-153.
94. Ho, Y.S., C.S. Lai, H.I. Liu, S.Y. Ho, C. Tai, M.H. Pan and Y.J. Wang, 2007. Dihydrolipoic acid inhibits skin tumor promotion through anti-inflammation and anti-oxidation. Biochem. Pharmacol., 73: 1786-1795.
95. Kim, H.S., H.J. Kim, K.G. Park, Y.N. Kim and T.K. Kwon *et al*., 2007. α-lipoic acid inhibits matrix metalloproteinase-9 expression by inhibiting NF-kB transcriptional activity. Exp. Mol. Med., 39: 106-113.
96. Karin, M. and F.R. Greten, 2005. NF-kB: Linking inflammation and immunity to cancer development and progression. Nat. Rev. Immunol., 5: 749-759.
97. Packer, L., E.H. Witt, H.J. Tritschler, K. Wessei and H. Ulrich, 1995. Antioxidant Properties and Clinical Implications of Alpha Lipoic Acid. In: Biothiols in Health and Disease, Packer, L. and E. Cadenas (Eds.). Marcel Dekker, New York, pp: 479-516.
98. Zhang, W.J. and B. Frei, 2001. α-Lipoic acid inhibits TNF-α-induced NF-κB activation and adhesion molecule expression in human aortic endothelial cells. FASEB J., 15: 2423-2432.
99. Alcaraz-Contreras, Y., L. Garza-Ocanas, K. Carcano-Diaz and X.S. Ramirez-Gomez, 2011. Effect of glycine on lead mobilization, lead-induced oxidative stress and hepatic toxicity in rats. J. Toxicol., Vol. 2011. 10.1155/2011/430539.
100. Aziz, F.M., I.M. Maulood and M.A.H. Chawsheen, 2012. Effects of melatonin, vitamin C and E alone or in combination on lead-induced injury in liver and kidney organs of rats. IOSR J. Pharm., 2: 13-18.
101. Rezk, R.G. and N.A. Abdel-Rahman, 2013. Protective effects of lipoic acid against oxidative stress induced by lead acetate and gamma-irradiation in the kidney and lung in albino rats. Arab J. Nucl. Sci. Applic., 46: 324-337.
102. Mahaffey, K., 1999. Nutriet-Led Interaction. In: Lead Toxicity, Singhal, R. and J. Thomas (Eds.). Urban and Schwarenbeg, Baltimore, Munich, pp: 425-460.
103. Osfor, M.M.H., H.S. Ibrahim, Y.A. Mohamed, S.M. Ahmed, A.S. Abd El Azeem and A.M. Hegazy, 2010. Effect of alpha lipoic acid and vitamin E on heavy metals intoxication in male albino rats. J. Am. Sci., 6: 56-63.
104. Pande, M. and S.J.S. Flora, 2002. Lead induced oxidative damage and its response to combined administration of α-lipoic acid and succimers in rats. Toxicology, 177: 187-196.
105. Biewenga, G.P., G.R.M.M. Haenen and A. Bast, 1997. The pharmacology of the antioxidant lipoic acid. Gen. Pharmacol.: Vasc. Syst., 29: 315-331.
106. Ou, P., H.J. Tritschler and S.P. Wolff, 1995. Thioctic (lipoic) acid: A therapeutic metal-chelating antioxidant? Biochem. Pharmacol., 50: 123-126.
107. Jubb, K.V.F., P.C. Kennedy and N. Palmer, 1985. Pathology of Domestic Animals. 3rd Edn., Academic Press, Inc., New York, USA., ISBN-13: 9780123916013, Pages: 574.
108. Jarrar, B.M., 2001. Ultrastructural alterations in proximal tubule cells induced by lead. Pak. J. Biol. Sci., 4: 1281-1284.
109. Jarrar, B.M. and Z.N. Mahmoud, 2000. Histochemical characterization of the lead intranuclear inclusion bodies. Biol. Trans. Elem. Res., 75: 245-251.